

The Proper Terminology for Reporting Lumbar Intervertebral Disk Disorders

Pierre C. Milette, *Centre Hospitalier de l'Université de Montréal (Quebec, Canada)*

Nature enjoys making fun of our classifications.

Pierre Masson (1880–1959)

Despite these somewhat disheartening words from the famous French pathologist, we should not give up solving the present mess associated with the reporting of intervertebral disk abnormalities in imaging studies. The present variations in the usage of language are responsible for confusion and controversy, and also compromise our chances of reaching a consensus on the diagnosis and treatment of disk disorders (1–5). As in other areas of medicine (eg, the TNM classification of tumors), it should be possible for diagnostic radiologists to rally round a

uniform nomenclature. Why has it been impossible so far? The historical lack of interest among traditional physicians, fundamental anatomists, and imaging specialists for the deemed trivial and vulgar issue of low back pain probably has something to do with it. Controversies regarding treatment, especially surgical indications, as well as legal and socioeconomic considerations, have also colored many debates. Over the last 10 years, several articles have dealt with the nomenclature of disk disorders in relation to the interpretation of imaging studies (6–16), but none of the proposed schemes has so far succeeded in generating universal acceptance.

Address reprint requests to Pierre C. Milette, MD, Department of Radiology, Centre Hospitalier de l'Université de Montréal, Saint-Luc Pavilion, 1058 Saint-Denis St, Montreal, Quebec, Canada H2X 3J4.

Index terms: Spine, intervertebral disks; Special reports

AJNR 18:1859–1866, Nov 1997 0195-6108/97/1810–1859 © American Society of Neuroradiology

In 1981, the American Academy of Orthopedic Surgeons published the *Glossary on Spinal Terminology* (17). In this work, the term *herniated nucleus pulposus* (considered synonymous with *intervertebral disk rupture*) was defined as “displacement of nuclear material and other disk components beyond the normal confines of the annulus.” Five categories of displacement were recognized: intraspongy nuclear herniation (Schmorl’s nodes), protrusion, incomplete herniation, extrusion, and sequestration. The definitions provided for some categories were ambiguous and more suitable for surgeons and pathologists than for radiologists reporting imaging studies. Some of the terms proposed in this nomenclature are still being used today, but with different definitions, which only add to the confusion. National and international radiologic societies have abstained thus far from dealing with this issue. In their approach to disk disorders, radiologists do not constitute a homogeneous group: the concepts of those who use diskography and interact daily with physiatrists and orthopedic surgeons are different from those of neuroradiologists who interact with neurologists and neurosurgeons (18).

The nomenclature to describe disk lesions has been greatly influenced by two factors: our concept of disk degeneration throughout life and our understanding of the physiopathology of clinically relevant disk disorders. Regarding the lumbar disk, our perception of what constitutes the normal aging process has been tailored by postmortem anatomic studies involving a small number of lumbar spine specimens, taken from persons from different age groups of whom very little was known, and who were simply presumed not to have suffered from disk disease (19–24). These studies did not lead to uniform conclusions. Eckert and Decker (20) noted that, with increasing age, there was swelling and hyalinization of the lamellae of the annulus fibrosus and that the nucleus pulposus showed the greatest changes, with a progressive increase in fibrous character and decrease in mucoid stroma. However, these authors did not observe radial fissures of the annulus or protrusions of the nucleus. Performing diskography on postmortem specimens, Kieffer et al (22) reported similar findings, but also found radial annular tears in 35% of disks removed from patients over 40 years old and concluded that disk rupture occurs frequently without signs and symptoms of nerve root compression. Although Kieffer et al did not conclude that annular radial tears were part of the normal aging process, this was the impression Bates and Ruggieri were left with, since they wrote, referring to this particular study, that radial tears were likely to be an incidental finding in the aging process (25). The series of cadavers investigated by Coventry et al (19) showed more severe changes, which lead these investigators to conclude that intervertebral disks retrogressed more rapidly and severely than most other tissues. These authors hypothesized that the constant use of intervertebral disks, as well as their susceptibility to trauma and their poor blood supply, doomed them to early and advanced degenerative changes. The confusion about the features of normal aging persists, as there are those who believe that the MR signal characteristics of

disks allow one to differentiate the normal aging process from pathologic degeneration (26) and those who think that this distinction is not possible (27) or that pathologic disk degeneration may just represent an acceleration of the normal aging process (12). The nomenclature one favors is directly related to one’s physiopathologic model. Radiologists of my generation have been taught that, as a result of sudden or chronic trauma, the incompressible nucleus can protrude through its fibrous wall (28); and should this occur in a posterior or posterolateral location and encroach on the neural canal, cord or nerve root pressure may result, with consequent segmental root pain and muscle spasm (29). The emphasis on developing imaging strategies that focus on the demonstration of lumbar disk herniations associated with nerve root compression is obvious in many of the articles published over the last 20 years (30–39), although the importance of associated congenital or acquired bone spinal stenosis has recently been recognized (40–45).

Under the influence of these two factors, a simple terminology requiring no effort to distinguish the normal aging process from pathologic degeneration was developed in the 1980s for the interpretation of myelograms and high-resolution CT scans: one needed only to choose among the normal disk, the bulging disk without nerve root compression, and the herniated disk with nerve root compression (33, 46). The validity of this model has been challenged in recent years, as it now appears that radicular pain is caused by inflammation of a nerve root, not by compression per se (47). This relatively new concept has led to the development of a new nomenclature, applicable to the interpretation of both MR and CT studies, that avoids most controversies and is based on an assessment of the disk contour without reference to nerve root compression (16). In this scheme, disks are classified as normal, bulge, protrusion, and extrusion (Fig 1) according to their shape, and more specifically the observed “disk extension beyond the interspace” (DEBIT). Further simplification of this terminology, in which the term *herniation* would be used to designate, collectively, protrusions and extrusions, has been suggested (12), but Brant-Zawadzki et al (16) suggest maintaining this distinction, because extrusions are rare in asymptomatic patients, as opposed to bulges and protrusions. Furthermore, these authors argue that the term *herniation* may be problematic by having too many ambiguous histologic implications, as well as a traumatic connotation, with a suggestion of inevitable clinical significance. Deyo et al (48) believe that physicians should be wary of labeling patients with frightening diagnoses, and that the term *ruptured disk*, for instance, implies a bursting or violent dissolution of tissue while the term *extruded disk* is less emotionally laden.

This terminology has the advantage of being simple. However, the assessment of the disk contour on axial CT or MR sections is not easy, and studies have shown that this particular terminology generates only moderate interobserver agreement, even when used by experienced neuroradiologists (16, 49). As an example, differentiating an extrusion from a protrusion may be difficult when dealing

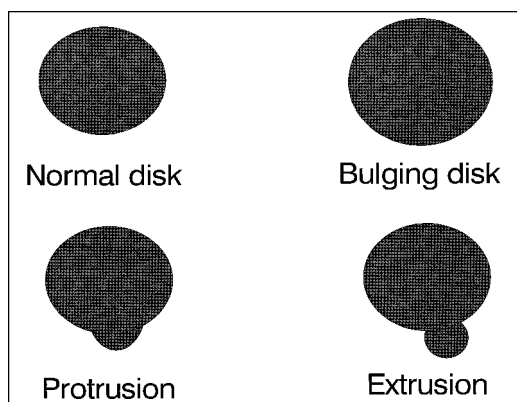


Fig 1. Schematic representation of a morphological nomenclature based on a two-dimensional assessment of the disk contour. *Normal disk*: absence of disk extension beyond the interspace (DEBIT). *Bulging disk*: circumferential, symmetric DEBIT (around the endplates). *Protrusion*: focal or asymmetric DEBIT; the base against the parent disk is broader than any other diameter of the protrusion. *Extrusion*: focal, obvious DEBIT; the base against the parent disk is narrower than the diameter of the extruded material itself, or there is no connection with the parent disk.

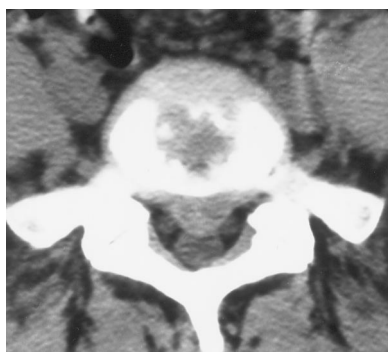


Fig 2. Axial CT section through L5-S1 shows rather large posterior central displacement of disk material, with slight dural sac compression. According to the definition, this displacement should qualify as a protrusion. However many observers will be inclined to use the word *extrusion* because of its large size.

with a narrow spinal canal, a foraminal herniation, or even a large central herniation (Fig 2). Initially conceived for the interpretation of axial CT sections, this classification considers the disk as a two-dimensional homogeneous structure and does not take into account intrinsic loss of the disk's integrity or alterations of the adjacent vertebral bodies. Modic and coworkers (50, 51) have documented, on MR images, vertebral body marrow changes associated with degenerative disk disease (types 1, 2, and 3). I believe such findings should be reported, because they represent clinically relevant information. Types 2 and 3 indicate a chronic process, whereas type 1 represents objective confirmation of an acute or subacute inflammatory disorder that may explain pain. Modifications of the MR disk signal—usually a decreased signal intensity on T2-weighted images—is a reliable indicator of physicochemical alter-

TABLE 1: Differential diagnosis of a bulging disk on CT or MR axial sections

- | |
|--|
| 1. Normal anatomic variant |
| 2. Illusion caused by volume-averaging effect |
| 3. Normal aging disk remodeling related to vertebral body osteoporosis |
| 4. Pathologic disk degeneration (deteriorated collapsed disk) |
| 5. Posterior disk rupture with subligamentous herniation |

ations that may be clinically relevant, and should also be reported; this nomenclature should therefore be expanded to provide a classification for disks with normal contour but abnormal signal intensity. The major problem with this nomenclature resides in the fact that it creates artificial pathologic entities. The bulging disk is defined as a disk that extends diffusely beyond the adjacent vertebral body margins in all directions, but its exact anatomic or pathologic nature remains a subject of great controversy. Yu et al (52), using cryomicrotome postmortem anatomic studies, found complete radial annular tears in most bulging disks, thus correcting the impression derived from earlier postmortem studies (45) that, even in young persons, a disk with an intact annulus may exhibit a detectable bulge on axial CT sections. A more recent hypothesis has been raised that bulging disks occur as a result of tears in the collagen bridges between the concentric annular fibers, thus producing diffuse laxity of the annulus while concentric annular fibers themselves remain intact (12). However, while studying the structure of the lumbar annulus fibrosus using a layer-by-layer peeling technique and microscopic examination of various cut surfaces, Marchand and Ahmed (53) found no sign of the presence of any such layer-to-layer connections or links. It is important to realize that the appearance of a diffuse "circumferential" disk bulging on a CT or MR axial section constitutes a visual finding requiring the elaboration of a differential diagnosis (Table 1). A bulging disk is not a pathologic entity, and I agree with Nachemson (54) that this term should not be offered as a diagnosis in radiologic reports.

Another nomenclature model, based on expected anatomy and pathology, has been proposed as a result of the development of two concepts (9). The first concept is that the normal aging process can indeed be differentiated from true pathologic degeneration. Resnick and Niwayama (55) have emphasized that the intervertebral disk can be affected by two different degenerative processes, one affecting the annulus fibrosus ("spondylosis deformans") and the other affecting the nucleus pulposus ("intervertebral osteochondrosis"). Data from other sources suggest that what is referred to as "spondylosis deformans" is nothing more than the normal aging process while "intervertebral osteochondrosis" corresponds to real pathologic deterioration and collapse of the disk, associated with bone erosion and reactive osteosclerosis (56–59). What we have learned so far about the normal aging process and the pathologic deterioration of a disk has been well summarized by Herzog (60). It appears, from pathologic studies and experimental animal models, that the

formation of a complete radial annular tear is the necessary condition for the progressive deterioration of a disk. Herzog suggests that this state of biomechanical disk failure be referred to as advanced disk disruption and degeneration to distinguish it from an aging disk that has not failed. The second concept that has inspired the development of the terminology I am about to present is that annular tears need to be diagnosed because they can cause low back pain and referred pain in the absence of modification of the disk contour. There is more and more evidence that "diskogenic pain" really exists, and that a disk rupture may cause radiating pain to an extremity in the absence of any direct contact between extruding disk material and a nerve root (61–64). Such pain may result from radial annular tears reaching the pain-sensitive external part of the annulus fibrosus. The advent of MR imaging has stimulated renewed interest in anatomic studies of the intervertebral disk and spinal ligaments (65–74). Postmortem studies have shown that MR imaging is a specific and sensitive method for detecting abnormal biochemical disk changes that precede structural changes (75). Diskography remains more sensitive than MR imaging for detecting radial annular tears (76) but these tears often cause a detectable decrease in signal intensity on T2-weighted MR images, sometimes associated with a peripheral focus of high signal intensity (77, 78). These tears may also enhance after intravenous injection of a paramagnetic contrast agent (79).

The particular nomenclature I am referring to considers the disk as a three-dimensional structure and is based on the expected anatomy and pathology of both the disk and adjacent vertebral bodies: disks are classified in the categories of a normal young disk, a normal aging disk, a scarred disk, an annular tear, and a herniated disk (Fig 3). This scheme can be applied to all imaging techniques, including plain films, and can be supplemented with the Dallas diskogram description (80) if CT diskography is being performed. In the case of plain CT, a pilot study free from superimposed reference lines can serve as an acceptable substitute to plain films for an assessment of the intervertebral space height. Diskography is not mandatory to diagnose annular tears, since a definite loss of central disk signal intensity, on T2-weighted MR images, is accepted as evidence of the presence of a major tear involving the outer annulus. The categories are not mutually exclusive, and all possible situations are covered. Mastering this nomenclature requires some time and effort, because assessment of multiple parameters is required to differentiate normal aging disks from truly degenerated or "scarred" disks (Table 2). The choice of the term *scarred disk* to designate pathologic degeneration and collapse was made with the histopathology in mind and with the intention of avoiding the ambiguity of the term *degenerated disk*. Unfortunately, this term can be misinterpreted as referring to postoperative changes. The term *chronic diskopathy* would probably constitute an acceptable alternative, although the term *deteriorated disk* would be my personal choice. Finally, the reliability of this nomenclature has never been tested: intraobserver and interobserver

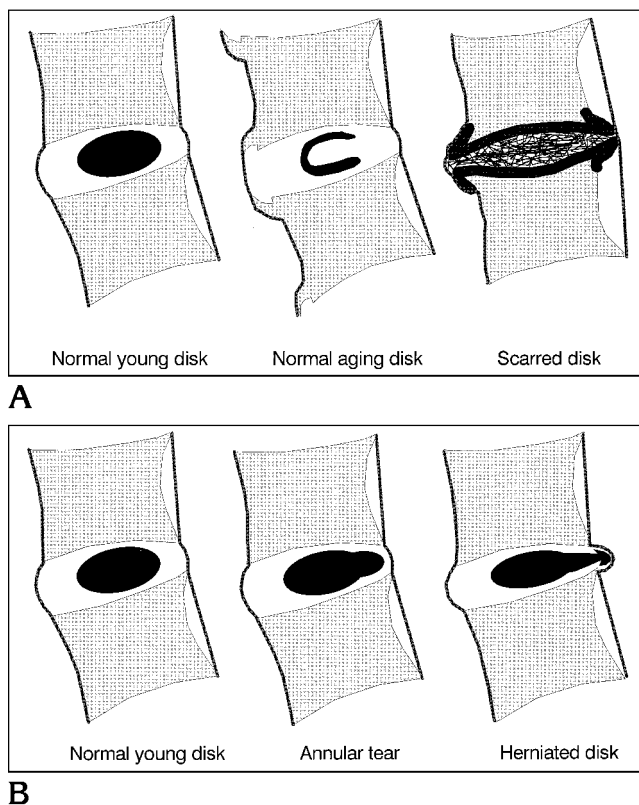


Fig 3. Schematic representation of a nomenclature based on a three-dimensional assessment of the anatomic and pathologic characteristics of both disk and adjacent vertebral bodies. The term *scarred disk* is meant to indicate chronic disk degeneration, deterioration, and collapse unrelated to previous surgery. The differentiating features between the *scarred disk* and the *normal aging disk* are indicated in Table 2. In this terminology, herniated disk is defined as a "focal displacement of disk material beyond the normal peripheral margin of the intervertebral disk space, corresponding to the original margins of the adjacent vertebral body endplates." Disk herniations are then further qualified according to the size and location of the displaced disk material.

variations in differentiating discrete herniations from pure annular tears are to be expected.

Regardless of which of the nomenclatures I have discussed one uses, the size and location of the disk material that is focally displaced beyond the normal peripheral margin of the intervertebral disk space also need to be specified in imaging reports. Although it is common practice, qualifying herniations (or protrusions/extrusions) as small, medium, or large is unreliable, because the size of the spinal canal is not considered. A simple scheme consists in roughly dividing the cross-sectional area of the spinal canal into thirds (anterior, middle, posterior) and in describing the displaced material accordingly. To specify its location in the spinal canal, I like the division into zones favored by the Nomenclature Committee of the North American Spine Society. These are, for the sagittal plane: diskal, suprapedicular, pedicular, and infrapedicular; for the horizontal plane: central, subarticular, foraminal, extraforaminal, and anterior. The demarcation between the

TABLE 2: Differentiating features of the normal aging disk and the scarred disk

Criterion	Normal Aging Disk	Scarred Disk
Clinical		
Age	Over 40 y	All ages
Symptoms	None	Frequent
History of low back pain	None	Frequent
Plain films and CT		
Disk space height	Normal	Decreased
Posterior disk margin	Regular	Irregular
Vertebral bodies	Normal	Osteosclerosis
Osteophytes	Anterolateral	All directions
Intradiskal gas	Anterolateral	Central
Number of affected disks	All	Variable
Additional criteria for MR		
Vertebral body marrow	Normal for age group	Type 2 or 3 changes*
Central disk signal intensity	Slight decrease	Marked decrease

* Classification proposed by Modic et al (50).

TABLE 3: Classification based on a clinical staging of lumbar diskopathy*

1. Low back pain \pm radiating pain. No objective sign.
2. Low back pain \pm radiating pain. Segmental pain, muscle spasm, and/or motion restriction.
3. Low back pain \pm radiating pain. Signs of dural or radicular irritation.
4. Low back pain \pm radiating pain. Neurologic deficit.

* *Diskopathy* is intended to mean any noninfectious or nonneoplastic disk lesion (annular tear, herniated disk, deteriorated disk); changes related to the normal aging process are excluded.

central and subarticular zone corresponds to the medial edge of the facets; the demarcation between the extraforaminal and anterior zone corresponds to the midcoronal plane of the vertebral body. For the foramina, a rough division between upper and lower parts is probably adequate. To report the separation of a disk fragment from the parent disk, the term *disk fragment migration* is less confusing than the term *sequestered disk*, which has a different meaning to a surgeon than to a diskographer contemplating chemonucleolysis. Additional comments about the integrity of the posterior longitudinal ligament, or about the location of the displaced disk material with respect to this ligament, can be added cautiously by those who are familiar with the modern anatomic concepts developed by Schellinger et al (69). With all these issues in mind, Bonnevillie (8, 10) has suggested an appealing five-point morphological classification of disk herniations, using letters, numbers, and signs, that may facilitate its international acceptance and statistical use. Finally, the term *intravertebral disk herniation* can still be applied to the special situation of cartilaginous (Schmorl's) nodes (81).

The required terminology to describe the size and location of displaced disk material is likely to be less controversial than the more fundamental issue discussed previously, namely: Which basic nomenclature should we adopt: one based on observed morphology of the disk contour or one based on predicted anatomy and pathol-

ogy? Attempts to straddle both schemes are doomed to failure. Trying to differentiate a herniated disk from a bulging disk is like trying to differentiate a truck from a motor vehicle. This problem has no solution because these two entities are not mutually exclusive and the terms refer to classifications established on a different basis: it should be obvious from Figure 3B that a posterior central subligamentous disk herniation, especially if associated with disk space narrowing and buckling of the anterior annulus, is one of the causes of a bulging disk appearance. An acceptable nomenclature should of course be useful for those reporting imaging studies, but it should also aim at conformity with macroscopic anatomy and pathology. This is essential to allow correlation with surgical and postmortem findings, which still constitutes the standard of reference for imaging specialists for the validation of any nomenclature. This is why I personally favor a nomenclature based on expected anatomy and pathology. I also think that we can and should distinguish changes resulting from the normal aging process from those caused by pathologic degeneration.

Ideally, the nomenclature used for imaging should also correspond to clinical entities and orient the referring physician as to treatment. Unfortunately, we will probably have to give up on that in the case of disk disorders. Abnormal findings have been reported by radiologists in asymptomatic subjects on plain radiographs (82–84), myelograms (85), diskograms (86, 87), CT scans (88), and MR images (89–93). Although the subjects in these published series all denied a history of significant low back pain, the lack of recall regarding low back pain has been well documented (94), and these studies do not allow us to conclude that the reported imaging abnormalities are part of the normal aging process. Nevertheless, they clearly support the notion that one must be careful before attributing causality to any abnormal finding in a symptomatic patient (95–97). Having acknowledged this problem, we must never forget that back pain is not an anatomic lesion but a symptom that primary care physicians have to deal with, very often long before a patient sees a surgeon (98).

Cases for which there is no surgical indication must often be evaluated by insurance companies or workers' compensation agencies, which presently have to cope with the ambiguities of our imaging reports. For the purpose of compensation, a nomenclature based on clinical rather than imaging findings would probably be the best solution (Table 3). The main objective of imaging studies, in that particular context, would be to support the clinical diagnosis by showing objective evidence of any kind of diskopathy (ie, annular tear, herniation, deteriorated disk) in a location consistent with the clinical findings. With such a scheme, the often discussed problem of interobserver agreement relative to the interpretation of imaging studies (16, 49, 99–102) would be curtailed, since an evaluation of whole-person impairment percentages would not generate litigation over the assessment of the disk contour to ascertain whether a "herniation of the nucleus pulposus" exists.

No individual can hope to achieve nomenclature standardization. I have tried to take stock of the present situation and provide a few practical guidelines for the daily reporting of imaging studies while we await some official consensus emanating from national or international societies. Let us hope this is not too far down the road.

References

- Andersson GBJ, Weinstein JN. Disc herniation (editorial). *Spine* 1996;21:1S
- Andersson GBJ, Brown MD, Dvorak J, et al. Consensus summary on the diagnosis and treatment of lumbar disc herniation. *Spine* 1996;21:75S–78S
- Fardon D, Pinkerton S, Balderston R, Garfin S, Nasca R, Salib R. Terms used for diagnosis by English speaking surgeons. *Spine* 1993;18:274–277
- Swartz JD. Letter from the guest editor: protrusion, extrusion. .. confusion! *Semin Ultrasound CT MRI* 1993;14:383–384
- Breton G. Is that a bulging disk, a small herniation or moderate protrusion? (editorial). *Can Assoc Radiol J* 1991;42:318
- Masaryk TJ, Ross JS, Modic MT, Bumphrey F, Bohlman H, Wilber G. High-resolution MR imaging of sequestered lumbar intervertebral disks. *AJNR Am J Neuroradiol* 1988;9:351–358
- Taveras JM. Radiologic aspects of low back pain and sciatic syndromes (editorial). *AJNR Am J Neuroradiol* 1989;10:451–452
- Bonneville JF. La carte-image des hernies discales lombaires. *Rachis* 1990;2:255–257
- Milette PC, Melanson D, Dupuis PR, et al. A simplified terminology for abnormalities of the lumbar disk. *Can Assoc Radiol J* 1991;42:319–325
- Bonneville JF. La topografia simbolica delle ernie discali lombari. *Riv Neuroradiol* 1992;5:427–431
- Kim KY, Kim YT, Lee CS, Shin MJ. MRI classification of lumbar herniated intervertebral disc. *Orthopedics* 1992;15:493–497
- Czervionke LF. Lumbar intervertebral disc disease. *Neuroimaging Clin N Am* 1993;3:465–485
- Thelander U, Fagerlund M, Friberg S, Larsson S. Describing the size of lumbar disc herniations using computed tomography. *Spine* 1994;17:1979–1984
- Yussen PS, Swartz JD. The acute lumbar disc herniation: imaging diagnosis. *Semin Ultrasound CT MRI* 1993;14:389–398
- Brant-Zawadzki M, Jensen M. Imaging corner: spinal nomenclature. *Spine* 1995;20:388–390
- Brant-Zawadzki MN, Jensen MC, Obuchowski N, Ross JS, Modic MT. Interobserver and intraobserver variability in interpretation of lumbar disc abnormalities. *Spine* 1995;20:1257–1264
- American Academy of Orthopedic Surgeons (1980): *Glossary on Spinal Terminology. Document 675–80*. Chicago: American Academy of Orthopedic Surgeons; 1981
- Bogduk N, Modic MT. Controversy: lumbar discography. *Spine* 1996;21:402–404
- Coventry MB, Ghormley RK, Kernohan JW. The intervertebral disc: its microscopic anatomy and pathology. *J Bone Joint Surg* 1945;27:105–112,233–247
- Eckert C, Decker A. Pathological studies of the intervertebral discs. *J Bone Joint Surg* 1947;29:447–454
- Hirsch C, Schajowicz F. Studies on structural changes in the lumbar annulus fibrosus. *Acta Orthop Scand* 1952;22:184–231
- Kieffer SA, Stadlan AM, Mohandas A, Peterson HO. Discographic-anatomical correlation of developmental changes with age in the intervertebral disc. *Acta Radiol Diagn* 1969;9:733–739
- Farfan HF, Huberdeau RM, Dubow HI. Lumbar intervertebral disc degeneration. *J Bone Joint Surg Am* 1972;54:492–510
- Pritzker KPH. Aging and degeneration of the lumbar intervertebral disk. *Orthop Clin North Am* 1977;8:65–77
- Bates D, Ruggieri P. Imaging modalities for the evaluation of the spine. *Radiol Clin North Am* 1991;29:675–690
- Sether LA, Yu S, Haughton VM, Fisher ME. Intervertebral disk: normal age-related changes in MR signal intensity. *Radiology* 1990;177:385–388
- Modic MT, Herfkens RJ. Devil's advocate: normal age-related changes in MR signal intensity. *Radiology* 1990;177:332–334
- Mixter WJ, Barr JS. Rupture of the intervertebral disc with involvement of the spinal canal. *N Engl J Med* 1934;211:210–214
- Murray RO. Skeletal trauma: regional. In: Sutton D, ed. *A Textbook of Radiology and Imaging*. 3rd ed. New York, NY: Churchill Livingstone; 1980:229
- Williams AL, Haughton VM, Syvertsen A. Computed tomography in the diagnosis of herniated nucleus pulposus. *Radiology* 1980;135:95–99
- Haughton VM, Eldevik OP, Magnaes B, Amundsen P. A prospective comparison of computed tomography and myelography in the diagnosis of herniated lumbar disks. *Radiology* 1982;142:103–110
- Williams AL, Haughton VM, Meyer GA, Ho KC. Computed tomographic appearance of the bulging annulus. *Radiology* 1982;142:403–408
- Kieffer SA, Sherry RG, Wellenstein DE, King RB. Bulging lumbar intervertebral disk: myelographic differentiation from herniated disk with nerve root compression. *AJR Am J Roentgenol* 1982;138:709–716
- Teplick JG, Haskin ME. CT and lumbar disc herniation. *Radiol Clin North Am* 1983;21:259–288
- Kieffer SA, Cacayorin ED, Sherry RG. The radiological diagnosis of herniated lumbar intervertebral disk: a current controversy. *JAMA* 1984;251:1192–1195
- Schipper J, Kardaun JWPF, Braakman R, van Donger KJ, Blaauw G. Lumbar disk herniation: diagnosis with CT or myelography? *Radiology* 1987;165:227–231
- Jackson RP, Cain JE, Jacobs RR, Cooper BR, McManus GE. The neuroradiographic diagnosis of lumbar herniated nucleus pulposus, I: a comparison of computed tomography (CT), myelography, CT-myelography, discography, and CT-discography. *Spine* 1989;14:1356–1361
- Jackson RP, Cain JE, Jacobs RR, Cooper BR, McManus GE. The

- neuroradiographic diagnosis of lumbar herniated pulposus, II: a comparison of computed tomography (CT), myelography, CT-myelography, and magnetic resonance imaging. *Spine* 1989;14:1363-1367
39. Thornbury JR, Fryback DG, Turski PA, et al. Disk-caused nerve compression in patients with acute low-back pain: diagnosis with MR, CT myelography, and plain CT. *Radiology* 1993;186:731-738
 40. Ciric I, Mikhael MA, Tarkington JA, Vick NA. The lateral recess syndrome. *J Neurosurg* 1980;53:433-443
 41. Dorwart RH, Vogler JB, Helms CA. Spinal stenosis. *Radiol Clin North Am* 1983;21:301-325
 42. Modic MT, Masaryk T, Boumphrey F, Goormastic M, Bell G. Lumbar disk disease and canal stenosis: prospective evaluation by surface coil MR, CT, and myelography. *AJR Am J Roentgenol* 1986;147:757-765
 43. Gaskill MF, Lukin R, Wiot JG. Lumbar disc disease and stenosis. *Radiol Clin North Am* 1991;29:753-764
 44. Kent DL, Haynor DR, Larson EB, Deyo RB. Diagnosis of lumbar spinal stenosis in adults: a metaanalysis of the accuracy of CT, MR, and myelography. *AJR Am J Roentgenol* 1992;158:1135-1144
 45. McCall IW. Radiology of spinal stenosis. *Acta Orthop Scand* 1993;64(Suppl 251):59-60
 46. Williams AL. CT diagnosis of degenerative disc disease. The bulging annulus. *Radiol Clin North Am* 1983;21:289-300
 47. Smyth MJ, Wright V. Sciatica and the intervertebral disc. *J Bone Joint Surg Am* 1958;40:1401-1418
 48. Deyo RA, Loeser JD, Bigos SJ. Herniated lumbar intervertebral disk. *Ann Intern Med* 1990;112:598-603
 49. Jarvik JG, Haynor DR, Koepsell TD, Bronstein A, Ashley D, Yogo RA. Interreader reliability for a new classification of lumbar disk disease. *Acad Radiol* 1996;3:537-544
 50. Modic MT, Steinberg PM, Ross JS, Masaryk TJ, Carter JR. Degenerative disk disease: assessment of changes in vertebral body marrow with MR imaging. *Radiology* 1988;166:193-199
 51. Modic MT, Masaryk TJ, Ross JS, Carter JR. Imaging of degenerative disc disease. *Radiology* 1988;168:177-186
 52. Yu S, Haughton VM, Sether LA, Wagner M. Annulus fibrosus in bulging intervertebral disks. *Radiology* 1988;169:761-763
 53. Marchand F, Ahmed AM. Investigation of the laminate structure of lumbar disc annulus fibrosus. *Spine* 1990;15:402-410
 54. Nachemson AL. Lumbar disc herniation: conclusions. *Acta Orthop Scand* 1993;64(Suppl 251):49
 55. Resnick D, Niwayama G. Degenerative disease of the spine. In: Resnick D, ed. *Diagnosis of Bone and Joint Disorders*. 3rd ed. Philadelphia, Pa: Saunders; 1995:1372-1462
 56. Sauser DD, Goldman AB, Kaye JJ. Discogenic vertebral sclerosis. *Can Assoc Radiol J* 1978;29:43-50
 57. Schmorl G, Junghanns H; Besemann EF, trans. *The Human Spine in Health and Disease*. 2nd ed. New York, NY: Grune & Stratton; 1971:186
 58. Nathan H. Osteophytes of the vertebral column. An anatomical study of their development according to age, race, and sex, with consideration as to their etiology and significance. *J Bone Joint Surg Am* 1962;44:243-268
 59. Twomey LT, Taylor JR. Age changes in lumbar vertebrae and intervertebral discs. *Clin Orthop* 1987;224:97-104
 60. Herzog RJ. The radiologic assessment for a lumbar disc herniation. *Spine* 1996;21:19S-38S
 61. Crock HV. Internal disc disruption. A challenge to disc prolapse fifty years on. *Spine* 1986;11:650-653
 62. Milette PC, Fontaine S, Lepanto L, Breton G. Radiating pain to the lower extremities caused by lumbar disk rupture without spinal nerve root involvement. *AJNR Am J Neuroradiol* 1995;16:1605-1613
 63. Schwarzer AC, Aprill CN, Derby R, Fortin J, Kine G, Bogduk N. The prevalence and clinical features of internal disc disruption in patients with chronic low back pain. *Spine* 1995;20:1878-1883
 64. Guyer RD, Ohnmeiss DD. Contemporary concepts in spine care: lumbar discography. *Spine* 1995;18:2048-2058
 65. Aguila LA, Piraino DW, Modic MT, Dudley AW, Duchesneau PM, Weinstein MA. The intranuclear cleft of the intervertebral disc: magnetic resonance imaging. *Radiology* 1985;155:155-158
 66. Pech P, Haughton VM. Lumbar intervertebral disk: correlative MR and anatomic study. *Radiology* 1985;156:699-701
 67. Ho PSP, Yu S, Sether LA, Wagner M, Ho KC, Haughton VM. Progressive and regressive changes in the nucleus pulposus, I: the neonate. *Radiology* 1988;169:87-91
 68. Ho PSP, Yu S, Sether LA, Wagner M, Ho KC, Haughton VM. Progressive and regressive changes in the nucleus pulposus, II: the adult. *Radiology* 1988;169:93-97
 69. Grenier N, Greselle JF, Vital JM, et al. Normal and disrupted lumbar longitudinal ligaments: correlative MR and anatomic study. *Radiology* 1989;197:197-205
 70. Schellinger DS, Manz HJ, Vidic B, et al. Disk fragment migration. *Radiology* 1990;175:831-836
 71. Tsuji H, Hirano N, Ohshima H, Ishihara H, Terahata N, Motoe T. Structural variation of the anterior and posterior annulus fibrosus in the development of human lumbar intervertebral disc: a risk factor for intervertebral disc rupture. *Spine* 1993;18:204-210
 72. Chatani K, Kusaka Y, Mifune T, Nishikawa H. Topographic differences of 1H-NMR relaxation times (T1, T2) in the normal intervertebral disc and its relationship to water content. *Spine* 1993;18:2271-2275
 73. Ohshima H, Hirano N, Osada R, Matsui H, Tsuji H. Morphologic variation of lumbar posterior longitudinal ligament and the modality of disc herniation. *Spine* 1993;18:2408-2411
 74. Bangaert BA, Modic MT, Ross JS, et al. Hyperintense disks on T1-weighted MR images: correlation with calcification. *Radiology* 1995;195:437-443
 75. Terzi M, Paaajanen H, Laato M, Aho H, Komu M, Kormanen M. Disc degeneration in magnetic resonance imaging: a comparative biochemical, histologic, and radiologic study in cadaver spines. *Spine* 1991;16:629-634
 76. Yu S, Haughton VM, Sether LA, Wagner M. Comparison of MR and discography in detecting radial tears of the annulus: a post mortem study. *AJNR Am J Neuroradiol* 1989;10:1077-1081
 77. Aprill C, Bogduk N. High-intensity zone: a diagnostic sign of painful lumbar disc on magnetic resonance imaging. *Br J Radiol* 1992;65:361-369
 78. Schellhas KP, Pollei SR, Gundry CR, Heithoff KB. Lumbar disc high-intensity zone. *Spine* 1996;21:79-86
 79. Ross JS, Modic MT, Masaryk TJ. Tears of the annulus fibrosus: assessment with Gd-DTPA-enhanced MR imaging. *AJNR Am J Neuroradiol* 1990;10:1251-1254
 80. Sachs BL, Vanharanta H, Spivey A, et al. Dallas discogram description: a new classification of CT/discography in low-back disorders. *Spine* 1987;12:287-294
 81. Resnick D, Niwayama G. Intervertebral disk herniations: cartilaginous (Schmorl's) nodes. *Radiology* 1978;126:57-65
 82. Torgerson WR, Dotter WF. Comparative roentgenographic study of the asymptomatic and symptomatic lumbar spine. *J Bone Joint Surg Am* 1976;58:850-853
 83. Witt I, Vestergaard A, Rosenklint A. A comparative analysis of X-ray findings of the lumbar spine in patients with and without lumbar pain. *Spine* 1984;9:298-300
 84. Frymoyer JW, Newberg A, Pope, MH, Wilder DG, Clements J,

- MacPherson B. Spine radiographs in patients with low-back pain. *J Bone Joint Surg Am* 1984;66:1048-1055
85. Hitzelberger WE, Witten RM. Abnormal myelograms in asymptomatic patients. *J Neurosurg* 1968;28:204-206
86. Holt EP. The question of lumbar discography. *J Bone Joint Surg Am* 1968;50:720-726
87. Walsh TR, Weinstein JN, Spratt KF, Lehmann TR, Aprill C, Sayre H. Lumbar discography in normal subjects. *J Bone Joint Surg Am* 1990;72:1081-1088
88. Wiesel SW, Tsourmas N, Feffer HL, Citrin CM, Patronas N. A study of computed-assisted tomography, 1: the incidence of positive CAT scans in an asymptomatic group of patients. *Spine* 1984;9:549-551
89. Weinreb JC, Wolbarsht LB, Cohen JM, Brown CEL, Maravilla KR. Prevalence of lumbosacral intervertebral disk abnormalities on MR images in pregnant and asymptomatic nonpregnant women. *Radiology* 1989;170:125-128
90. Boden SD, Davis DO, Dina TS, Patronas NJ, Wiesel SW. Abnormal magnetic-resonance scans of the lumbar spine in asymptomatic subjects. *J Bone Joint Surg Am* 1990;72:403-408
91. Jensen MC, Brant-Zawadzki MN, Obuchowski N, Modic MT, Malkasian D, Ross JS. Magnetic resonance imaging of the lumbar spine in people without back pain. *N Engl J Med* 1994;331:69-73
92. Erkintalo MO, Salminen JJ, Alanen AM, Paajanen HEK, Kormanen MJ. Development of degenerative changes in the lumbar intervertebral disk: results of a prospective MR imaging study in adolescents with and without low-back pain. *Radiology* 1995;196:529-533
93. Ricketson R, Simmons JW, Hauser BO. The prolapsed intervertebral disc: the high-intensity zone with discography correlation. *Spine* 1996;21:2258-2762
94. Carey TS, Garrett J, Jackman A, Sanders L, Kalsbeek W. Reporting of acute low back in a telephone interview: identification of potential biases. *Spine* 1995;20:787-790
95. Modic MT, Ross JS. Morphology, symptoms and causality. *Radiology* 1990;175:619-629
96. Milette PC, Raymond J, Fontaine S. Comparison of high-resolution computed tomography with discography in the evaluation of lumbar disc herniations. *Spine* 1990;15:525-533
97. van Tulder MW, Assendelft WJJ, Koes BW, Bouter LM. Spinal radiographic findings and nonspecific low back pain. *Spine* 1997;22:427-434
98. Deyo RA, Philips WR. Low back pain: a primary care challenge. *Spine* 1996;21:2826-2832
99. Eisenberg RL, Hedgcock MW, Gooding GAW, DeMartini WJ, Akin JR, Ovenfors CO. Compensation examination of the cervical and lumbar spines: critical disagreement in radiographic interpretation. *AJR Am J Roentgenol* 1980;134:519-522
100. Beers GJ, Carter AP, Leiter BE, Tilak SP, Shah RR. Interobserver discrepancies in distance measurements from lumbar spine CT scans. *AJR Am J Roentgenol* 1985;144:395-398
101. Coste J, Paolaggi JB, Spira A. Reliability of interpretation of plain lumbar spine radiographs in benign, mechanical low-back pain. *Spine* 1991;16:426-428
102. Raininko R, Manninen H, Battié MC, Gibbons LE, Gill K, Fisher LD. Observer variability in the assessment of disc degeneration on magnetic resonance images of the lumbar and thoracic spine. *Spine* 1995;20:1029-1035